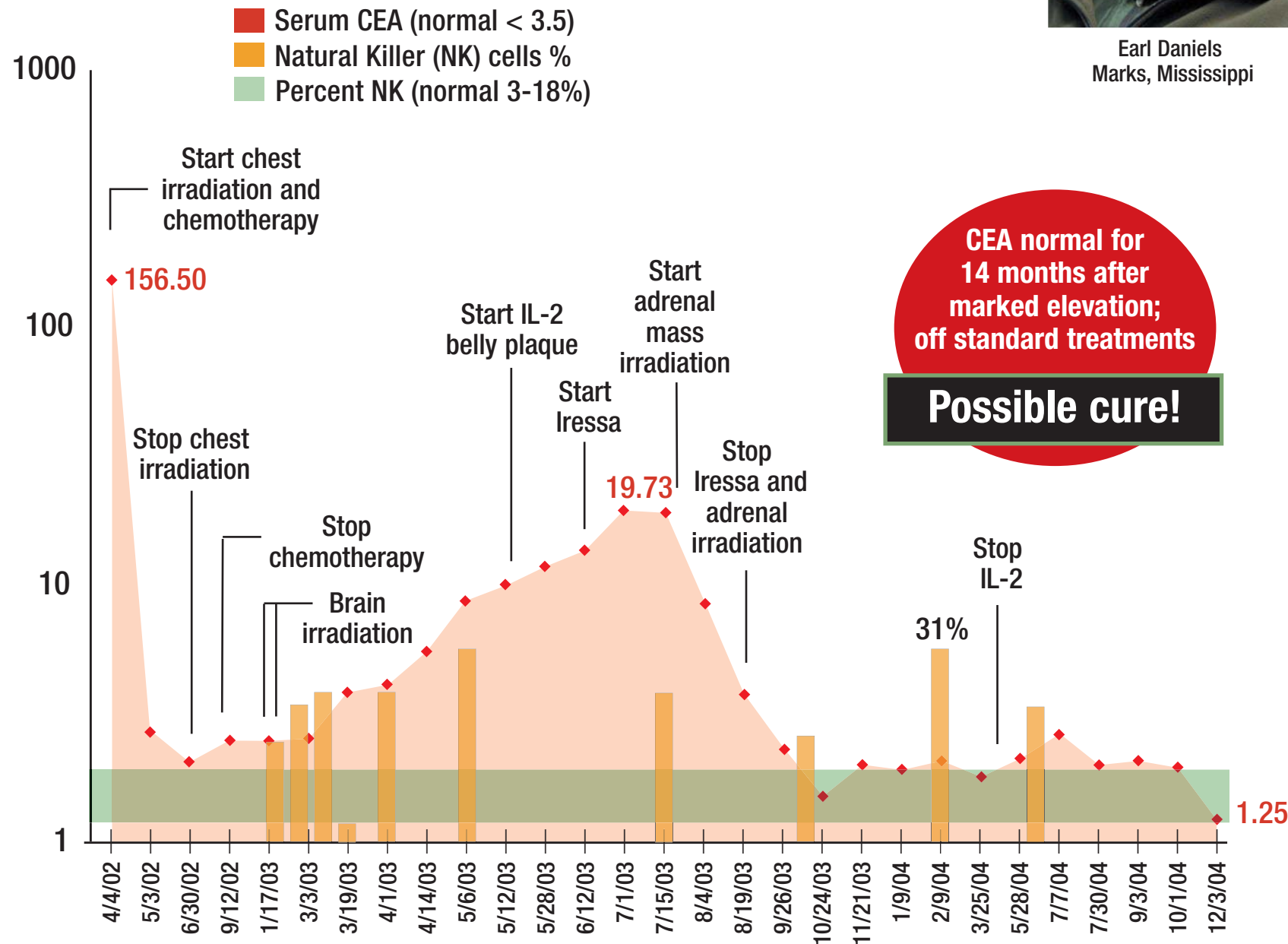


Adenocarcinoma of the Lung: Brain and Adrenal Metastases

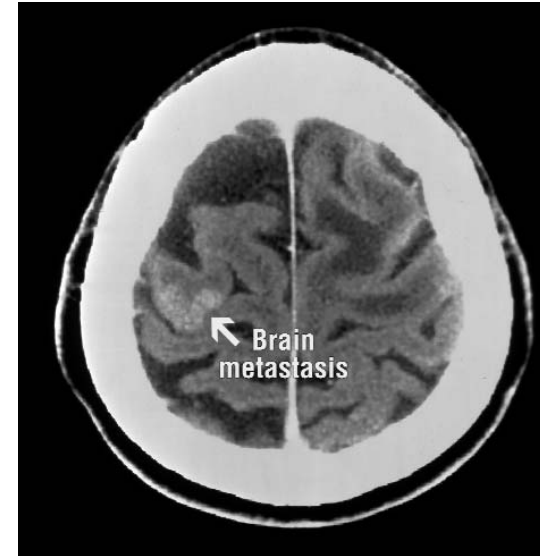Keeping the Grim Reaper at Bay in a Deadly Condition



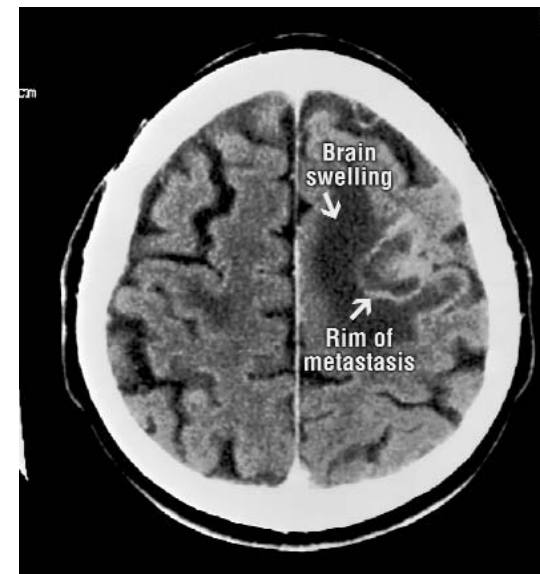Earl Daniels
Marks, Mississippi



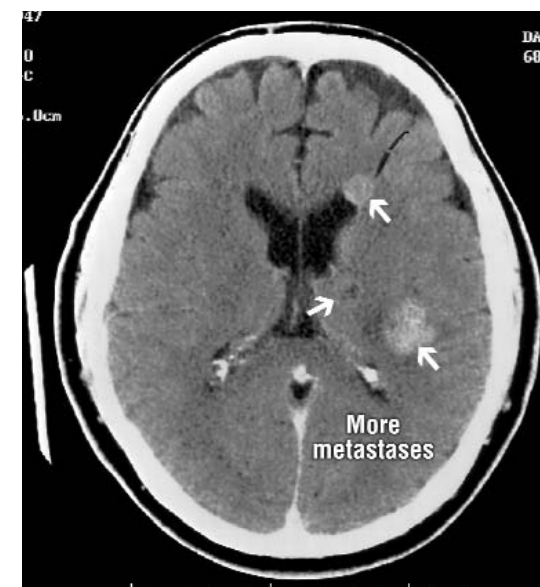
CT scan with contrast 11/15/02



Upper slice



Middle slice



Lower slice

**Prohibited:
Immune Restorative
Therapy at Work**



Current BRM Regimen

- | | | | | |
|-----------|---------------------|-----------------------------|-----------------------|--------------------|
| Vitamin E | Aspirin | Saw palmetto | Bromocriptine | Miatake fraction D |
| Selenium | Methyl testosterone | Melatonin | Cimetidine | Transfer factor |
| DHEA | Pregnenolone | Sustained release vitamin C | Ascorbic acid aqueous | ImmKine |